

SIMSYS Scan Report

Date: 10 / 22 / 2012

Patient: Piotr Wywrot

Number: 7700552

Notes:

The features identified using the 7-point checklist suggest that the lesion is not suspicious. Inspection and review of the five views presented below make it clear that this lesion is not a melanoma. Recommend patient return for a follow up scan in 4 months.

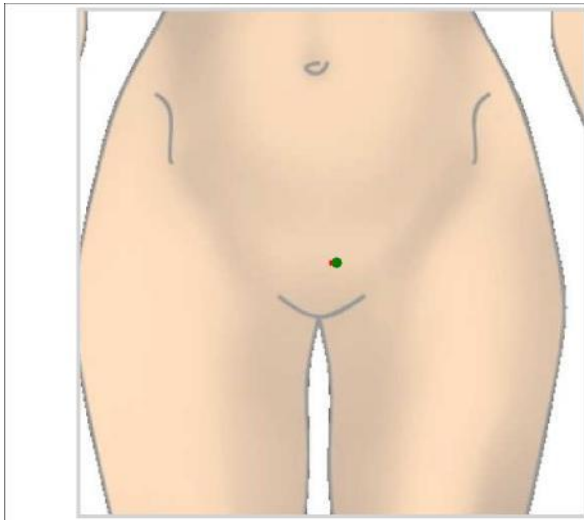
Thomas Smith, M.D.



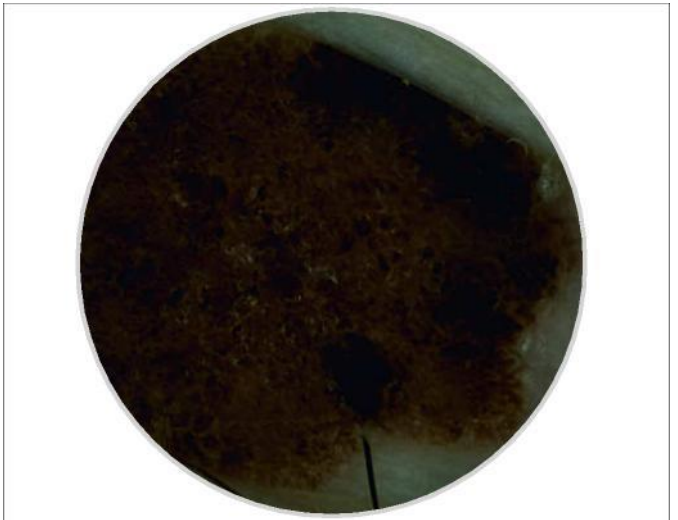
Patient:
7700552
File name:
Image_193.sia

Date:
24 2012

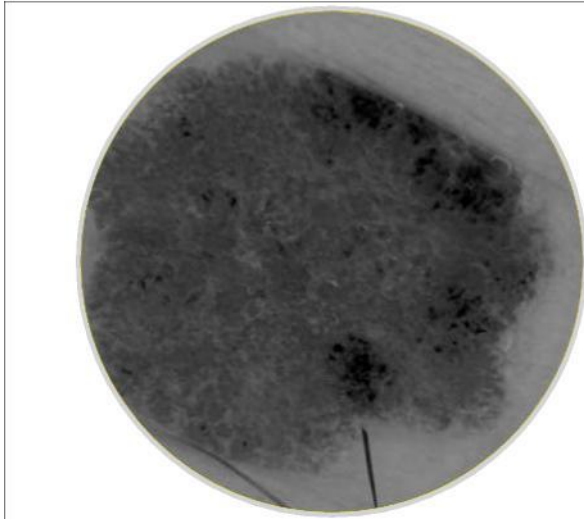
Confidential



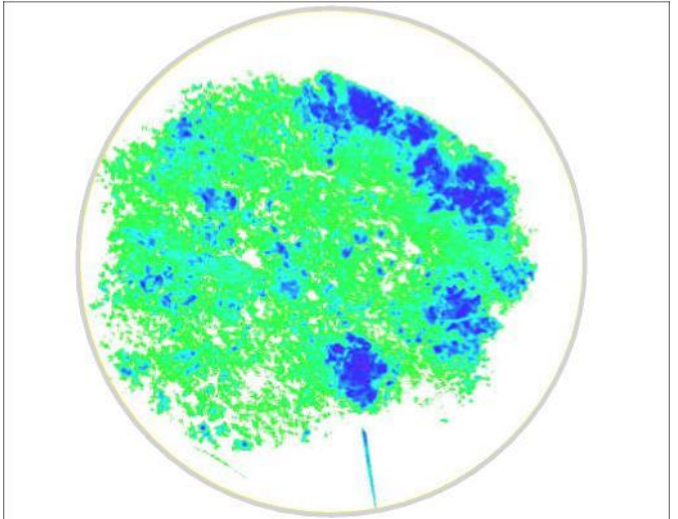
Location



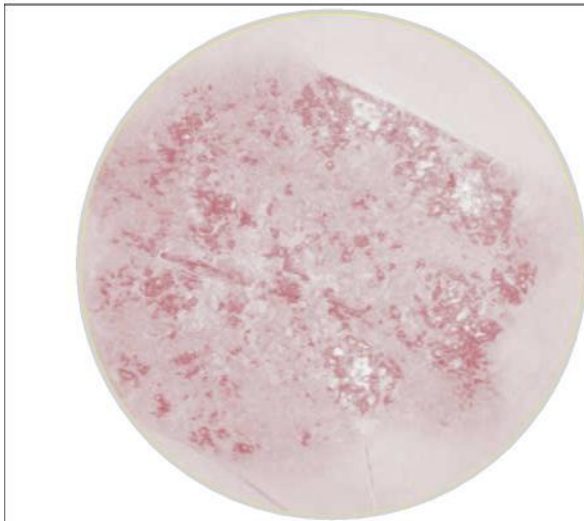
Colour



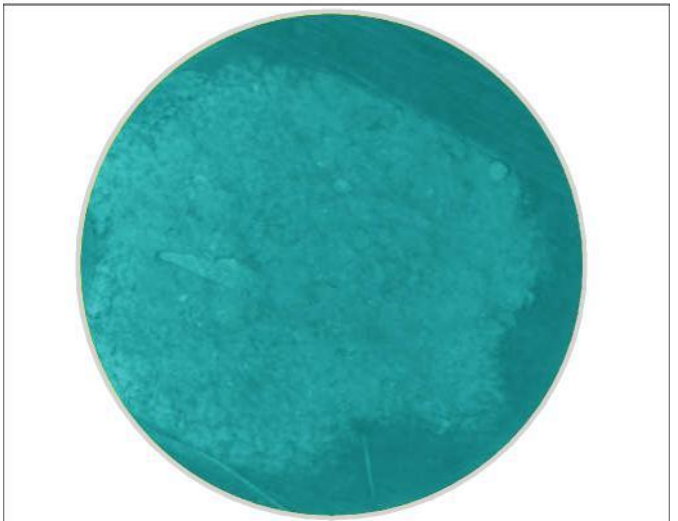
Melanin



Dermal melanin



Blood



Collagen